

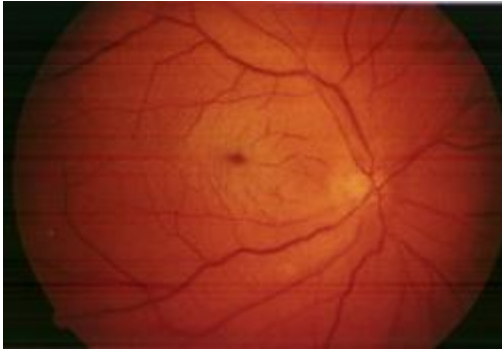

Image 1: Central Retinal Artery Occlusion




Image 2: Central Retinal Vein Occlusion